

Using magnetically tagged data to better understand the mechanical function of normal and abnormal hearts.

VOLUMETRIC HEART MODELING AND ANALYSIS

By **KYOUNGJU PARK, ALBERT MONTILLO, DIMITRIS METAXAS, and LEON AXEL**

Hearth disease is the leading cause of death in the Western world and consequently the study of normal and pathological heart behavior is an active research area. In particular, the study of the shape and motion of the heart is important because many heart diseases are strongly correlated to these two factors. The human heart is composed of two separate pumps: a right heart that pumps the blood through the lungs and a left heart that pumps the blood through the peripheral organs. In turn, each of these “hearts” is a two-chamber pump composed of an atrium and a ventricle. Special mechanisms in the heart provide cardiac rhythm and transmit action potentials throughout the heart muscle to cause the heart’s rhythmic relaxation (diastole) and contraction (systole).




Figure 1. The essential data needed (boundaries and tag lines) from each MRI-SPAMM short-axis image: (left) End-diastole short-axis view; (right) Mid-contraction short-axis view.

Understanding the heart's mechanics is crucial for clinical research, as well as for diagnosis and patient care. Imaging techniques, such as magnetic resonance imaging (MRI), ultrasound, computed tomography (CT), and X-ray, provide noninvasive methods to study internal organs in vivo. Frequently, 2D slices can be combined to generate a 3D volumetric model. The images taken over time make 4D (3D plus time) analysis possible, but accurate and efficient interpretation of this data is difficult to achieve. These modalities can provide a tremendous amount of data and when presented as 2D images typically require an expert anatomist to interpret. Moreover, comprehensive understanding of diastole and systole is difficult because as the heart beats some structures become invisible and then visible again as they move through the fixed image planes acquired by the scanner. Image interpretation is further confounded by artifacts caused by the motion of the subject. The cost of full manual interpretation of the data by a cardiology/radiology specialist is prohibitive for routine data analysis. An automated analysis system, however, holds the promise of reducing interpretation costs and is the first step toward an objective, quantitative analysis rather than a subjective, qualitative analysis. In addition, an automated analysis system may be used to study correlation between particular diseases and the regional changes in the shape and motion of the heart.

Problem Statement

For our research, we use a magnetically tagged MRI technique called SPAMM (SPAtial Modulation of Magnetization [2]). The advantage of the SPAMM technique over other imaging techniques, such as ultrasound and Positron Emission Tomography (PET) [10], is that a number of material points within the myocardium walls can be marked noninvasively and

tracked, providing the true 3D motion of the heart muscle over time. With conventional imaging methods, tracking is limited to the shape of the inner and outer contours of the heart wall. Our data typically consists of three sets of images of the heart: two contain a short-axis view and one contains a long-axis view. We combine these sets to track 3D material points in the heart.

The primary method for analyzing cardiac image data, a manual method in which an expert anatomist guides a geometric model to fit the data, is inherently dependent upon the clinician's ability. We seek to develop an automated analysis method to reduce subjectivity, cost, and the amount of time required for analysis. Furthermore, we desire to develop quantitative analysis to add depth to the knowledge of the mechanical function of normal and abnormal hearts. An automated analysis must address the following tasks:

- Extraction of 3D information from the 2D slices;
- Computation of correspondence: the exact motion of the living tissue over time;
- Generation of the anatomically correct heart model;
- Provisions for normal variations with the underlying geometric model; and
- Relation of the acquired geometric and motion data to specific diseases.

Due to the complicated shape of the heart, we use finite-element modeling to find the distribution of strain throughout the heart during contraction. In addition, when prior knowledge of the material properties of the heart is available, we can incorporate this into the model and use constitutive equations based on continuum mechanics to compute regional stress.

In our analyses we employ a deformable model-based method for the automatic segmentation and analysis of the heart's volume from images and the finite element modeling method for estimating the mechanical properties of the heart muscle. Our method allows for patient-specific analysis of the heart's mechanical function.

Related Work in Heart Modeling and Analysis

In recent years, modeling and motion analysis of the heart has been done successfully for the left ventricle (LV) [1, 3, 9, 10, 12]. The LV was modeled with an

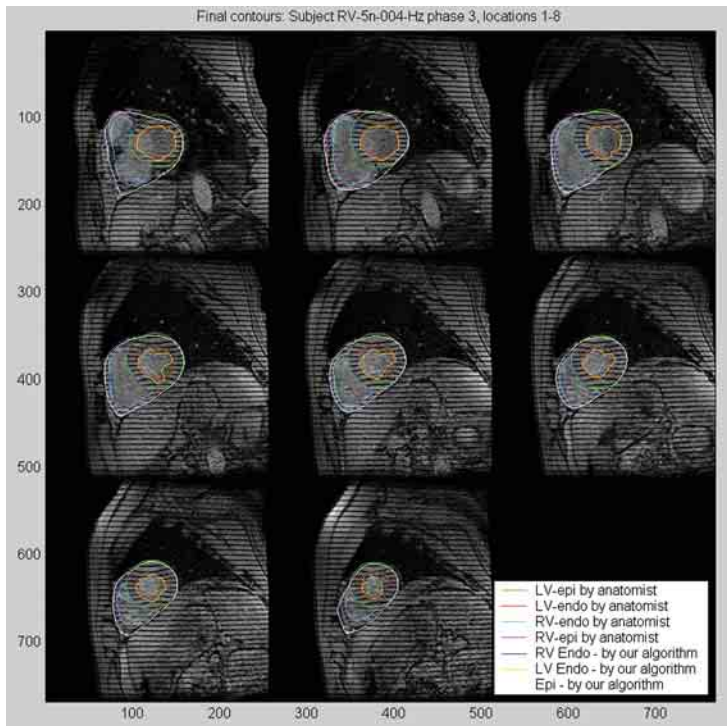


Figure 2. Sample results from the automated boundary detection algorithm for the LV and RV and inflow and outflow tracts of the RV.

iso-surface using prolate spheroidal coordinates; B-splines [1] were used to model the LV. Parameter functions [12] led to a good description of the LV shape and motion. The shape and motion over time were estimated and represented in terms of appropriate parameters.

Methods employing 3D deformable models for cardiac image analysis have been used mainly for the LV. Most of these methods designed the LV model as a generalization of a superellipsoid. There have been some initial trials to study the right ventricle (RV) [4], the geometry of which is much more complex. The RV endocardium, consisting of free wall and septum wall, looks like a crescent moon in cross section and has both inflow and outflow tracts at the base.

A clinically useful method for the automated 3D analysis of the shape and motion of the whole heart does not yet exist. 3D modeling can provide visualization of the heart's shape, which must be imagined when only 2D images are used in clinical practice. 4D modeling can accurately depict the motion of the heart during systole and diastole and has the potential to effect an earlier disease diagnosis.

Deformable Models

In the past two decades, the deformable model approach has been highlighted in graphics, vision, entertainment, and medical applications. Deformable models are widely used for modeling and animation of nonrigid objects and many approaches have been developed. The deformation of objects has been simulated based on physics; real-time deformation has been possible with some assumptions. In medical applications, accurate simulation of soft tissue properties is most important, even at the cost of speed and simplicity. By leveraging constitutive equations derived from the theory of elasticity, the finite-element method (FEM) can accurately model soft tissue mechanics. Therefore, in medical applications the FEM is used for computational modeling.

The model-based approach has shown its strength in medical image analysis, where accuracy is paramount under often uncertain data. Even insufficient information can be

used to generate a reasonable model when combined with an underlying generic model: we can take advantage of prior shape information and guess a similar initial shape. The model should be able to cover the variations of the object. However, the complexity and variability of the heart's shape in humans makes it difficult to generate an appropriate deformable model.

Here, we present a concise and generic method of representing the 3D heart shape for cardiac image analysis [11]. Our method uses a Boolean operation technique from solid modeling for the deformable model. We build a blended shape deformable model using deformable model primitives. The initial shape is designed in an anatomically correct way. The model has three walls: LV endocardium, RV endocardium, and whole outer wall. Each wall is partitioned according to its spherical coordinates and those elements are connected with the corresponding elements in another wall to build a volumetric Finite Element model of the heart. The model reconstructs a patient-specific 3D heart shape by adaptively varying a set of parameter functions. The refinement of the parameter functions is determined in terms of how well the model recovers the shape dictated by its fit to the boundary data points segmented from SPAMM images. In our approach, we

3D MODELING CAN PROVIDE VISUALIZATION OF THE HEART'S

SHAPE, which must be imagined when only 2D images are used in clinical practice.

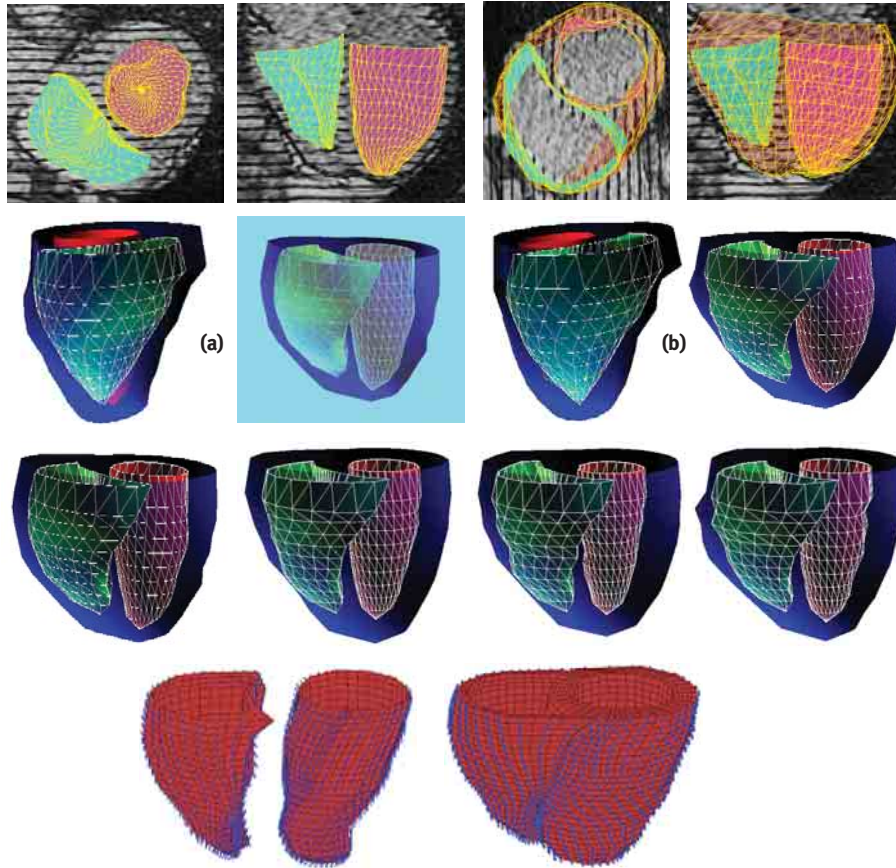


Figure 3. The top row shows the estimation of the LV-RV endocardium and the epicardium on the MRI-tagged slices for a normal heart. The second row shows a normal and an abnormal heart at end-diastole. The RV endocardium of the RV hypertrophy patient is significantly larger than that of normal heart: (a) Normal heart (b) RV hypertrophy heart. The third row shows the heart model's motion during systole. Finally, the fourth row shows a finite element model of the ventricles derived from MRI, with local fiber angles (blue) derived from in vitro data superimposed at corresponding locations in (left) subendocardium and (right) subepicardium.

usually take 12 short-axis imaging slices and nine long-axis imaging slices during systole. The end-diastolic 3D heart is reconstructed and shape evolution for the end-diastolic has not been defined.

Model Geometry

Most model-based research on the heart has been done on the left ventricle due to its simple shape and importance for circulating blood. The shape of the LV resembles that of an ellipsoid and can be easily reconstructed using ellipsoids with parameter functions [12]. However, the complicated shape of the whole heart, including LV, RV, left atrium, and right atrium, makes it difficult to create a full mathematical model of the heart.

To model the heart effectively, we use blending of deformable primitives [11]. Blending can be described using the physical analogy of cutting surfaces apart and gluing them together. The result of the blending cre-

ates a broader representational class of deformable primitives. Blending starts with two underlying shapes, which are then mapped into a new domain. Combining two shapes to form a blended shape involves the specification of the retained parts of these shapes, as well as how overlapping parts are connected together. Using this method, we can create an anatomically correct and mathematically sound heart model.

Our technique creates a blended deformable primitive with spatially varying parameter functions to model the LV and RV ventricles [11]. The LV shape is based initially on the superellipsoid primitive by replacement of the constant parameter with differentiable parameter functions [12]. The RV shape is based initially on

the blending of two superellipsoid primitives with parameter functions. Two superellipsoids are blended to make the plane sections crescentic. Then each wall is defined with a latitude-longitude parameterization using the material coordinates $\mathbf{u} = (u, v)$. These initial shapes then deform based on the FEM approach to capture the exact shape of the combined LV-RV model. The structural relation of the LV and RV are defined using relation parameters. The relation parameters include the relative translation and rotation of RV to the LV.

Segmentation of the Heart and Tags

One of the most time-consuming processes in tagged MR-based heart analysis is the extraction of the tags and boundaries [4, 7, 9, 11]. The more laborious and time-consuming of these two processes is the extraction of the boundaries (Boundary extraction is even more difficult in other modalities such as ultrasound [10]). Figure 1 shows results of a manual process that takes between 5–10 hours, depending on the level of detail traced. This process requires an expert anatomist to initialize and guide active contours called snakes to the endocardium and epicardium and then initialize and guide a family of parallel active contours to the tags.

It is important to track the surfaces of the heart, not

just the tags. The surfaces are used to improve the computation of tag tracking and can help identify and track the location of key anatomical features for intersubject analyses. The heart surfaces can be used directly to measure ejection-fraction and wall thickness, and can be used as the initial conditions for a fluid mechanics solver to simulate patient-specific blood-flow patterns [6] and to initialize a finite element model for strain analysis [11]. Since typically 80% of the time needed by the analyst is used to delineate the walls of the LV and RV, we have developed a segmentation process that locates these contours automatically, alleviating this task for the anatomist (see Figure 2). Researchers such as [3] have attempted to address this problem, their focus has been primarily on locating the walls of the larger, more readily segmented LV and the results have typically required significant manual correction of up to 25% of the contours. The endocardium is difficult to locate because there is often little intensity contrast between the blood and the myocardium, or a variable intensity of the blood throughout the RV and LV cavities. The epicardium is difficult to segment because it is often occluded by other structures in the body such as a layer of fat, the liver, and the chest wall, which can have similar intensity to the myocardium.

Our method consists of a sequence of image-processing steps, followed by the computation of forces in each image plane and then the evolution of a deformable model until convergence is reached [8]. Our approach can: account for intensity nonuniformities introduced by the surface coils used in the imaging process [8]; automatically segment the heart's boundaries during contraction based on the use of intensity statistics; automatically initialize a volumetric model [8]; and, automatically extract and embed the tag lines in the volumetric model.

Shape Reconstruction and Motion Analysis

Based on the automated segmentation of the heart's boundaries and tag lines, we create dynamic models that deform due to forces computed from the data [11]. The model converges to the desired shape when the external forces diminish to zero and the residual motion is negligible.

The estimation process (see Figure 3) involves the

numerical integration of the Lagrange equations of motion over time and the use of nonlinear finite element theory. The resulting stresses and strains, including heart fiber orientation, are then computed and used for the analysis of cardiac function and the differentiation between diseased and normal conditions [5, 11].

Potential of Automated Analysis

While qualitative evaluation of regional heart wall motion from imaging such as MRI is already useful, the quantitative data that can be provided by automated analysis of tagged MRI data is much more valuable. Overcoming previous barriers posed by time-consuming manually based analysis methods will allow us to quantitatively analyze the 3D motion effects of important clinical conditions, such as myocardial ischemia, hypertrophy, or failure, and to follow such patients over time. This will lead to both better understanding of these diseases and better management of patients affected by the particular diseases.

The principal limitation of these methods is the quality of the images being analyzed. Imaging artifacts, blurring due to limited resolution, and misregistration due to patient motion may all compromise the effectiveness of fully automated analysis and lead to the need for some interactive guidance in such cases. However, the deformable model approach should provide a robust means of regularizing the problem of motion reconstruction in such cases.

Conclusion

We have developed methods to automatically extract the boundaries of the heart and the tags in SPAMM images. Our blended deformable models with parameter functions can give a concise and quantitative description of the heart shape and its motion. These shape parameter functions can be used for classification of the normal heart shape with a suitable training set. The motion analysis also provides very important information: because some diseases are related to alterations of the heartbeat, we can determine the relation between the heart wall motion, blood flow, and disease [6]. The regional wall motions also inform where abnormal motion occurs. Furthermore, modeling the stress-strain relationship of the ventricle wall makes it

Our method consists of a sequence of image-processing steps, followed by the computation of forces in each image plane and then the evolution of a deformable model **UNTIL CONVERGENCE IS REACHED.**

possible to estimate the material properties of the ventricle [5]. ■

REFERENCES

1. Amini A., Radeva, P., Elayyadi, M., and Li, D. Measurement of 3D motion of myocardial material points from explicit B-surface reconstruction of tagged MRI data. In *Proceedings of MICCAI* (1998), 110–118.
2. Axel, L., and Dougherty L. MR imaging of motion with spatial modulation of magnetization. *Radiology* 171 (June 1989), 841–845.
3. Guttman M.A., Prince J.L., and McVeigh, E.R. Tag and contour detection in tagged MR images of the left ventricle. *IEEE Transactions on Medical Imaging* 13, 1 (1994), 74–88.
4. Haber, I., Metaxas, D., and Axel, L. Three dimensional motion reconstruction of the right ventricle using tagged MRI. *Medical Image Analysis* 4, 4 (Dec. 2000), 335–355.
5. Hu, Z., Metaxas, D., and Axel, L. In vivo strain and stress estimation of the heart left and right ventricles from MRI images. *Medical Image Analysis* 7, 4 (Dec. 2003), 435–444.
6. Jones, T., and Metaxas, D. Patient-specific analysis of left ventricular blood flow. *Image Computing and Computer-Assisted Intervention—MICCAI* (Cambridge, MA, Oct. 1998), 156–166.
7. Kerwin, W., Osman, N., and Prince, J. Image processing and analysis in tagged cardiac MRI. In I. Bankman, Ed., *Handbook of Medical Imaging: Processing and Analysis*, 2000.
8. Montillo, A. Automated volumetric model construction and dynamic segmentation of the heart ventricles in tagged MRI. Ph.D. thesis, University of Pennsylvania, 2004.
9. Ozturk, C., and McVeigh, E. Four-dimensional B-spline-based motion analysis of tagged cardiac MR images. In *Proceedings of SPIE Medical Imaging 99*, (San Diego, CA, Feb 1999).
10. Papademetris, X., Sinusas, A., Dione, D., and Duncan, J. Estimation of

3D left ventricular deformation from echocardiography. *Medical Image Analysis* (2001).

11. Park, K., Metaxas, D., and Axel, L. A finite element model for functional analysis of 4D cardiac-tagged MR images. In *Proceedings of MICCAI 2003* (Montreal, Canada), 491–498.
12. Park, J., Metaxas, D., and Axel, L. Analysis of left ventricle wall motion based on volumetric deformable models and MRI-SPAMM. *Medical Image Analysis* 1, 1 (1996), 53–81.

KYOUNGJU PARK (kypark@graphics.cis.upenn.edu) is a postdoctoral fellow at Rutgers University Division of Computer and Information Sciences.

ALBERT MONTILLO (albertmontillo@yahoo.com) is a research assistant professor at the Rutgers University Department of Biomedical Engineering and the Division of Computer and Information Sciences.

DIMITRIS METAXAS (dnm@cs.rutgers.edu) is a professor of Computer Science and Biomedical Engineering and the director of the Center for Computational Biomedicine, Imaging, and Modeling at Rutgers, the State University of New Jersey.

LEON AXEL (leon.axel@med.nyu.edu) is a professor of radiology and the director of Cardiac Imaging at the New York University School of Medicine.

Permission to make digital or hard copies of all or part of this work for personal or classroom use is granted without fee provided that copies are not made or distributed for profit or commercial advantage and that copies bear this notice and the full citation on the first page. To copy otherwise, to republish, to post on servers or to redistribute to lists, requires prior specific permission and/or a fee.

© 2005 ACM 0001-0782/05/0200 \$5.00

2005

EDITORIAL CALENDAR FOR

COMMUNICATIONS OF THE ACM

- March** The Disappearing Computer
- April** Transforming China
- May** Distributed Auto-Adaptive and Reconfigurable Systems
- June** 3D Hard Copy
- July** Designing for Mobility
- August** Spyware
- September** RFID Technologies and Issues
- October** Technology and Societal Influences
- November** The State of Computer Security
- December** The Semantic E-Business Vision